

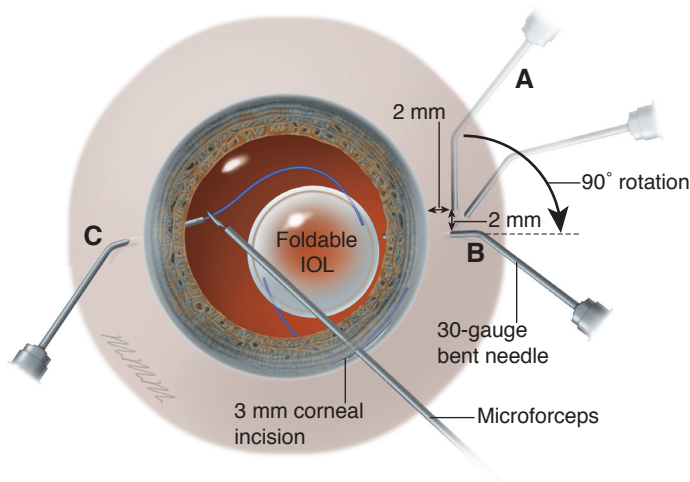Figure 11-10 Illustration of intrascleral flanged haptic IOL fixation (Yamane technique). **A**, Transconjunctival scleral tunnels (180° apart) are made parallel to the limbus 2 mm posterior to the limbus with thin-walled (wide-bore) 30-gauge needles. Each tunnel is approximately 2 mm long. **B**, The needles are turned perpendicular (arrow) to the limbus to enter the eye. **C**, The leading haptic of a 3-piece foldable IOL is guided into the bore of the needle with microforceps under direct visualization. The same is done for the trailing haptic, and both are simultaneously externalized where noncontact thermal cautery is used to create a flange prior to replacement into the sclera (not shown; see Video 11-4). (Illustration courtesy of Mark Miller.)



VIDEO 11-4 Ab externo flanged-haptic IOL fixation, Yamane technique.
Courtesy of Charles Cole, MD.



VIDEO 11-5 Double-needle intrascleral flanged haptic IOL fixation, Yamane technique.
Courtesy of Wesley Green, MD, and Arsham Sheybani, MD.



VIDEO 11-6 Ab externo IOL reposition with Hoffman pockets.
Courtesy of Jason Leng, MD.



by-products of trapped, residual lens epithelial cells (Fig 11-12). Myopic shift is uncommon in these cases, and the patient may be asymptomatic. Nd:YAG laser posterior capsulotomy usually resolves this condition without complications.

Uveitis-Glaucoma-Hyphema Syndrome

UGH syndrome was first described in the context of rigid or closed-loop ACIOLs, as described in the Appendix. In modern surgery, it may also occur in patients with posterior chamber lenses owing to contact between lens haptics and uveal tissue in the posterior

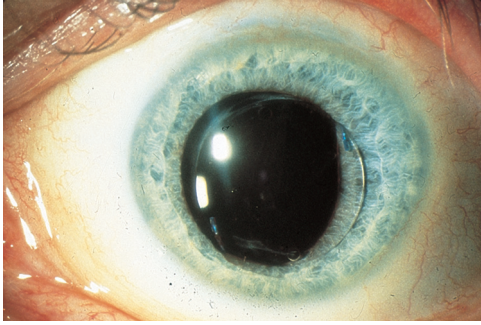


Figure 11-11 Pupillary capture by an angulated posterior chamber IOL in a patient who was assaulted 2 months after lens implantation surgery. (Courtesy of Steven I. Rosenfeld, MD.)

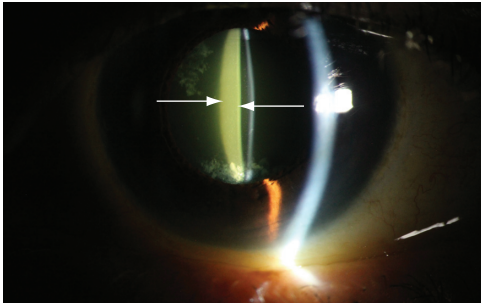


Figure 11-12 Late postoperative capsular block. Arrows show the posterior edge of the IOL and the posterior capsule containing turbid fluid. (Courtesy of Chad Brasington, MD.)

chamber. Single-piece acrylic IOL haptics should not be placed in the sulcus because of the high risk of UGH syndrome. The classic triad or individual components of the syndrome may also occur as a result of inappropriate IOL sizing, contact between the implant and vascular structures or the corneal endothelium, or defects in implant manufacturing.

Uveitis, glaucoma, and/or hyphema may respond to treatment with cycloplegics and topical anti-inflammatory or ocular hypotensive medications. If medical therapy does not sufficiently address the findings or if inflammation threatens either retinal or corneal function, IOL removal must be considered. This procedure may be complicated because of inflammatory scars, particularly in the anterior chamber angle or posterior to the iris. If such scarring is present, the surgeon may need to amputate the haptics from the optic and remove the lens piecemeal, rotating the haptic material out of the synechial tunnels to minimize trauma to the eye. In some cases, it is safer to leave portions of the haptics in place. Early lens explantation may reduce the risk of corneal decompensation and CME.

Pseudophakic Bullous Keratopathy

Certain IOL designs, particularly iris-clip lenses (iris-fixated lenses with the optic anterior to the iris) and closed-loop flexible anterior chamber lenses as described in the Appendix, have been associated with an increased risk of corneal decompensation. Iris-clip lenses have been shown to contact the corneal endothelium during eye movement, whereas closed-loop ACIOLs are associated with endothelial cell loss, thought to be due to chronic inflammation and contact between the lens and peripheral corneal endothelial cells. Thus, these 2 lens types are no longer in clinical use.