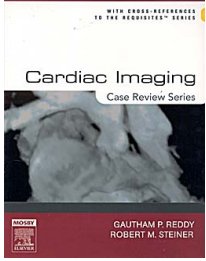


CARDIAC IMAGING, CASE REVIEW

	Autor:	Steiner
	ISBN:	9780323011761
	Páginas:	224
	Año:	2006
	Edición:	1
	Idioma:	Ingles
Disponible:	De 2 a 3 Semanas	
Precio:	49.04 46.56	Iva no incluido

DESCRIPTION:

Over 200 cases with 400 images cover both acquired and congenital heart disease. Each case is presented as an unknown with several questions. On the opposite page appears the diagnosis, responses to questions, additional commentary, and cross-references. The full spectrum of cases provided offers perfect exam preparation for residents or clinical review for practicing physicians. Cross-references to CARDIAC RADIOLOGY: THE REQUISITES.

CONTENTS:

- Case 1: Aortic Valve Disease
- Case 2: Aortic Stenosis-Pseudoaneurysm of Ascending Aorta
- Case 3: Bicuspid Aortic Valve - Aortic "Ulcer"
- Case 4: Aortic Regurgitation-Aortic Valve Calcification
- Case 5: Annuloaortic Estasia-Rheumatic Aortic Disease
- Case 6: Takayasu Arteritis
- Case 7: Marfans Syndrome
- Case 8: Coarctation Aorta
- Case 9: Pseudocoarct Aorta
- Case 10: Cervical Arch
- Case 11: Postoperative Aortic Coarctation Pseudoaneurysm
- Case 12: Post-Traumatic Pseudoaneurysm: Recent and Remote
- Case 13: Type I Dissection
- Case 14: Type II Dissection
- Case 15: Type III Dissection
- Case 16: Atherosclerotic Aneurysm
- Case 17: Right Arch Mirror Image
- Case 18: Right Arch with Aberrant Left Subclavian Artery
- Case 19: Left Aortic Arch with Aberrant Right Subclavian Artery
- Case 20: Ductus Diverticula with Patent Ductus Arteriosus
- Case 21: Calcified Ligamentum Arteriosum
- Case 22: Sinus of Valsalva Aneurysm
- Case 23: Mitral Valve Prolapse in Patient with Asthenic Habitus - Mitral Annulus Calcification-Asthenic Habitus
- Case 24: Mitral Regurgitation
- Case 25: Mitral Stenosis
- Case 26: Mitral Stenosis with Calcified Valve
- Case 27: Mitral Regurgitation with RUL Pulmonary Edema
- Case 28: Dilated Cardiomyopathy
- Case 29: Constrictive Pericarditis
- Case 30: Pericardial Cyst (right side)
- Case 31: Pericardial Fibroma
- Case 32: Pericardial Metastases
- Case 33: Pericardial Mesothelioma
- Case 34: Post Myocardial Infarction Syndrome
- Case 35: SLE with Pericardial and Pleural Effusion
- Case 36: Calcific Pericarditis
- Case 37: Restrictive Cardiomyopathy
- Case 38: Hypertrophic Cardiomyopathy
- Case 39: Asymmetrical Septal Hypertrophy
- Case 40: Subaortic Stenosis
- Case 41: Hypertrophic Cardiomyopathy Secondary to Systemic Hypertension
- Case 42: Tricuspid Regurgitation
- Case 43: Tricuspid Regurgitation due to Vegetation in Drug Abuse

Case 44: AIDS Related Cardiomyopathy
Case 45: Ebsteins Anomaly
Case 46: ASD, Secundum
Case 47: ASD, Primum
Case 48: ASD, Sinus Venosus
Case 49: VSD Muscular Septum
Case 50: VSD Membranous Septum
Case 51: Double Outlet Rt Ventricle
Case 52: Pulmonary Valvular Stenosis
Case 53: Pulmonary Valvular Stenosis with Asymmetrical Pulmonary Blood Flow
Case 54: Absence of the Right Pulmonary Artery
Case 55: Absence of Pulmonary Valve in Patient with Tetralogy of Fallot
Case 56: Right Venticular Arrhythmogenic Hypoplasia
Case 57: Transposition of the Great Vessels
Case 58: Corrected Transposition of the Great Vessels
Case 59: Tetralogy of Fallot
Case 60: Tricuspid Atresia
Case 61: Truncus Arteriosus I
Case 62: Truncus Arteriosus II
Case 63: Pulmonary Atresia and VSD
Case 64: Tetralogy of Fallot with Right Aortic Arch
Case 65: Pulmonary Hypertension, Primary
Case 66: Pulmonary Hypertension, Eisenmenger Physiology
Case 67: Pulmonary Hypertension Related to Chronic Sarcoidosis
Case 68: Pulmonary Hypertension due to Severe Emphysema
Case 69: Overcirculation due to Severe Anemia in a Sickle Cell Patient
Case 70: Pulmonary Venous Hypertension with Vascular Cephalization
Case 71: Hemosiderosis due to Mitral Stenosis
Case 72: Osler-Weber-Rendu Syndrome
Case 73: Scimitar Sign-Partial Anomalous Pulmonary Venous Return
Case 74: Total Anomalous Pulmonary Venous Return
Case 75: Pacemaker Lead Perforation of RV "Snowman" Heart
Case 76: Fractured Pacemaker Lead
Case 77: Prosthetic Valve Dislodgment
Case 78: Twiddlers Syndrome
Case 79: Torn Patch in Patient with Implanted Defibrillator
Case 80: Strut Damage in Aortic Valve Prosthesis with Acute Aortic Regurgitation
Case 81: Pulmonary Venous Varis
Case 82: Total Anomalous Pulmonary Venous Return Below the Diaphragm
Case 83: Hypoplastic Left Heart Syndrome
Case 84: Small Heart in Patient with Addisons Disease
Case 85: Blalock-Taussig Procedure
Case 86: Fontan Procedure
Case 87: Glenn Shunt
Case 88: Potts Procedure
Case 89: Waterston Shunt

LIBRERIA MEDICA BERRI 2024 ®

Dirección: Ald. Urquijo, 35 48010 Bilbao | Tlf.: 94 444 22 85 | Fax: 94 410 07 20 | libros@berri.es | www.berri.es